

Creation of an image archive to preserve the value of the University of Bristol chelonian collection

Rebecca Hitchman, Imogen Richens¹ and Cathy Fuller¹

¹Centre for Applied Anatomy, University of Bristol

Introduction

The Centre for Applied Anatomy, University of Bristol, owns a precious set of chelonian specimens and prosections as valuable anatomy teaching tools for undergraduate students. Some of these have been in the department for many years and are an invaluable tool, both for teaching purposes and for study. Preserving these chelonian specimens is important due to the difficulty of procuring and prosecting them. The aim of this project was to create a digital archive to preserve and help protect the teaching specimens as well as allowing access as an online resource.

Methodology

The images were taken using a Fujifilm Finepix HS35EXR camera with the following settings: image quality Fine, ISO Auto (800) and using macro and standard shots depending on the level of detail required from the photograph. The specimens were placed on standard plain black card paper in a well-lit room to ensure differentiation between the background and specimen details. Each specimen was photographed from many different angles to highlight defining details. The photographs were uploaded onto a computer and Microsoft PowerPoint 2016 image editing tools were used to enhance the sharpness, between 20-30%, and contrast between 5-20%. The image editing helped to compensate for the age and formaldehyde treatment of the specimens which had caused fading and muting of colours. Serif PhotoPlus was also used to remove the paper background of the image and replace it with a plain black background. This prevented the texture of the paper and any shadow cast by the specimen detracting from the finer details of the skin and shell demonstrated by Figure 1.

Specimens that best represented the position of the key organs were labelled using PowerPoint 2016 to allow for use in lectures as well as for independent study by students, shown in Figure 2.

The white text was enhanced using the 'glow' effect in black to ensure the labels were clear to read and contrasted from the varying textures of the specimen. To make sure the labels were accurate Bairbre O'Malley (2005) was referenced.

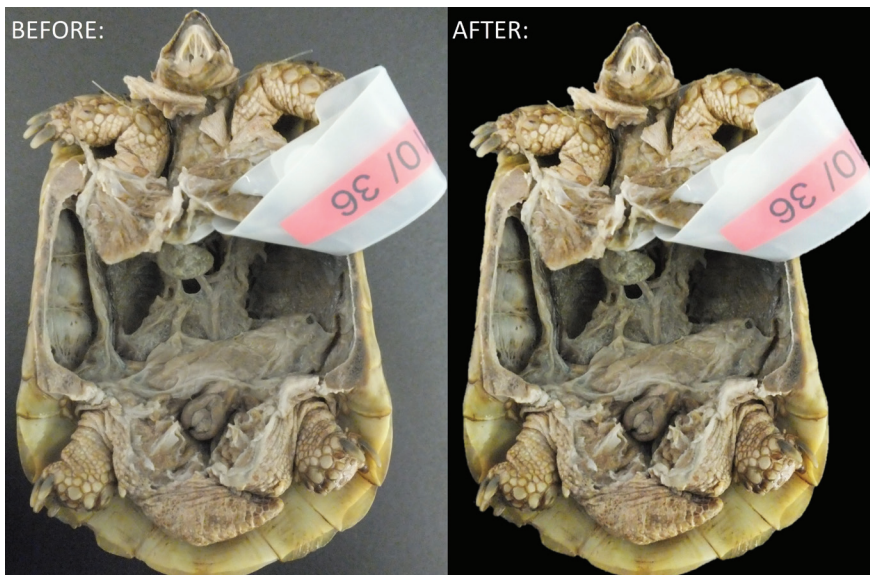


Fig. 1. The image before and after editing via the methods stated.

Results

Twenty-four specimens were successfully photographed and preserved digitally, a process that took a month. Lecturers can now easily access the resources to enhance taught material and students can use the labelled and unlabelled counterparts to test their knowledge on chelonian anatomy. The online tool is an important resource that can easily and effectively be used to maintain high teaching standards whilst minimising damage to the actual specimens.

For example, an area that highlights the delicate nature of chelonian anatomy is within the mouth. The tongue has a rough appearance with the glottis tucked at the back and the choanae are clear on the roof of mouth. These features would be difficult to appreciate without having the muscles of the mandible cut open. This action means that the mandible is more delicate to handle, and the structures more susceptible to damage. They are also features that students can often overlook, as not all specimens have been prosected in a manner that allows for the features in the mouth to be appreciated. However, these features are easily studied and appreciated by the student using the appropriate photos as seen in Figure 3.

Another example of photographs aiding study and identification of chelonian anatomy is in the difference between male and female reproductive tracts. This is especially important in the male as the highly pigmented epididymis (Fig. 4) is often mistaken for kidney (Fig. 5) when learning. This

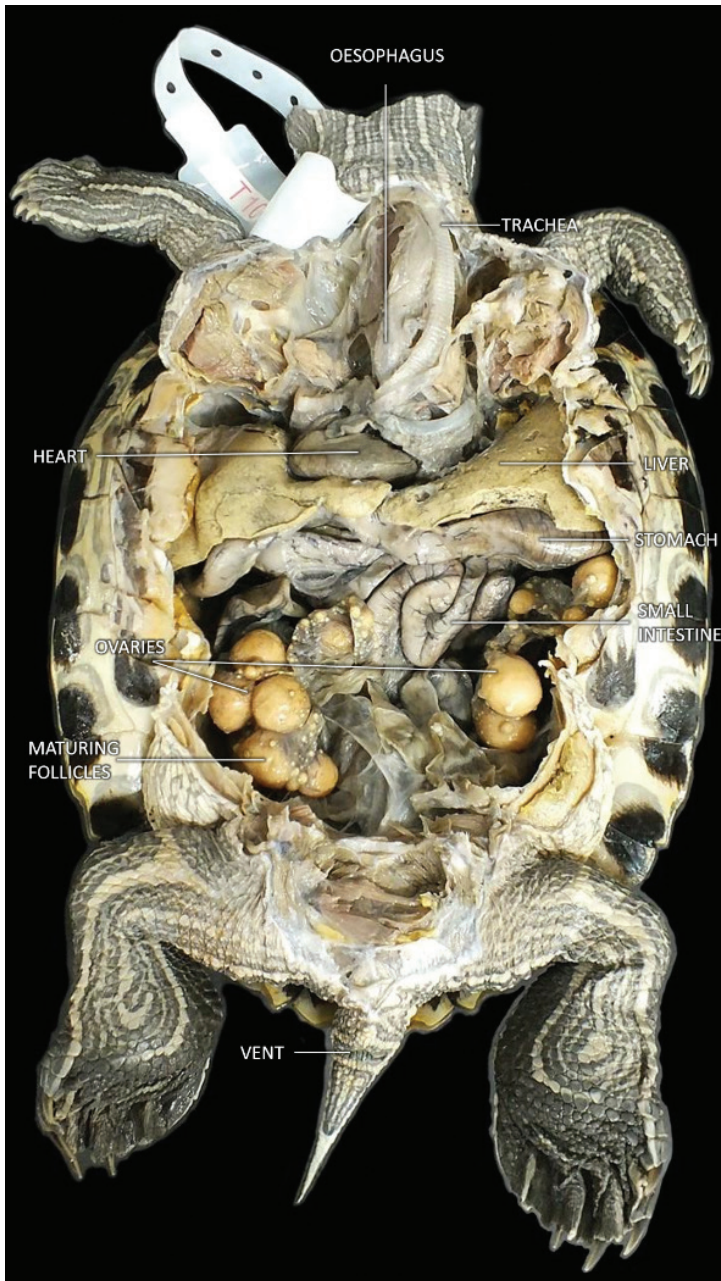


Fig. 2. Labelled image using the technique described.

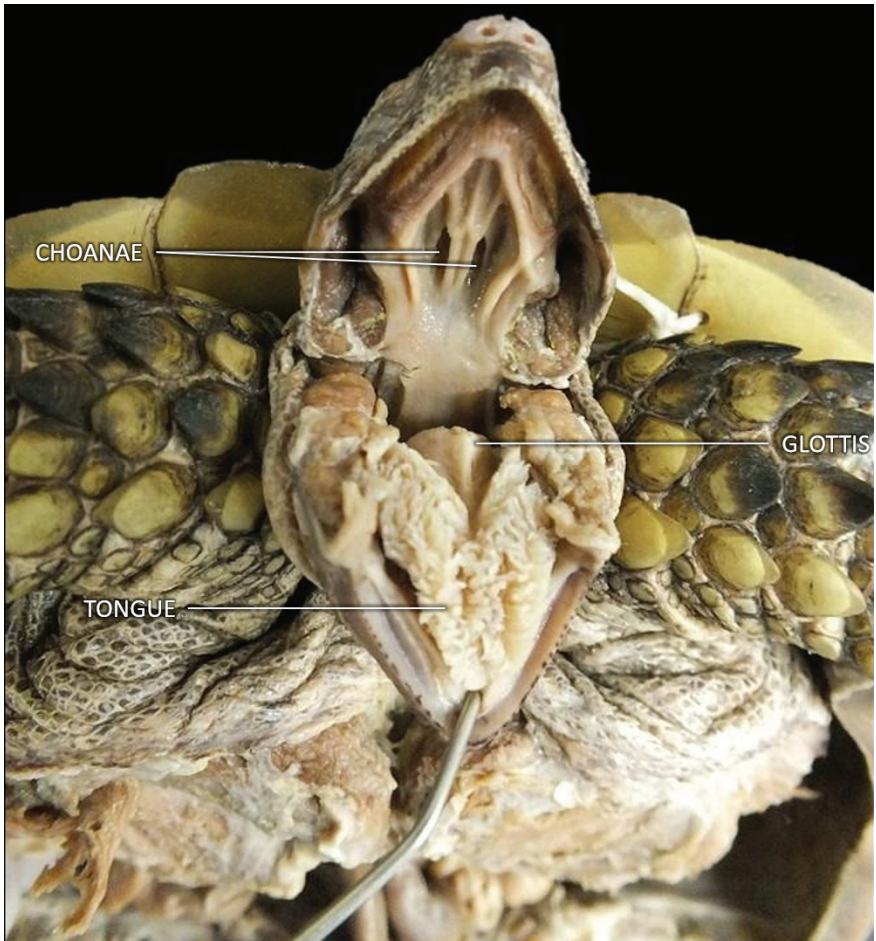


Fig. 3. The internal features of the tortoise mouth.

is because the kidneys are located retroperitoneally (i.e. at the back of the abdominal cavity behind the other organs) and therefore are not visible in most specimens due to the abdominal contents.

Discussion

There is little literature focussing on chelonian anatomy available for study. An online bank of images which is readily accessible allows these to be used alongside textbooks to allow people to truly appreciate the appearance of chelonian anatomy. Further work could embrace other imaging modalities, for example integrating videos demonstrating dynamic anatomy of the specimens, or radiography. In conclusion, the creation of a digital record of

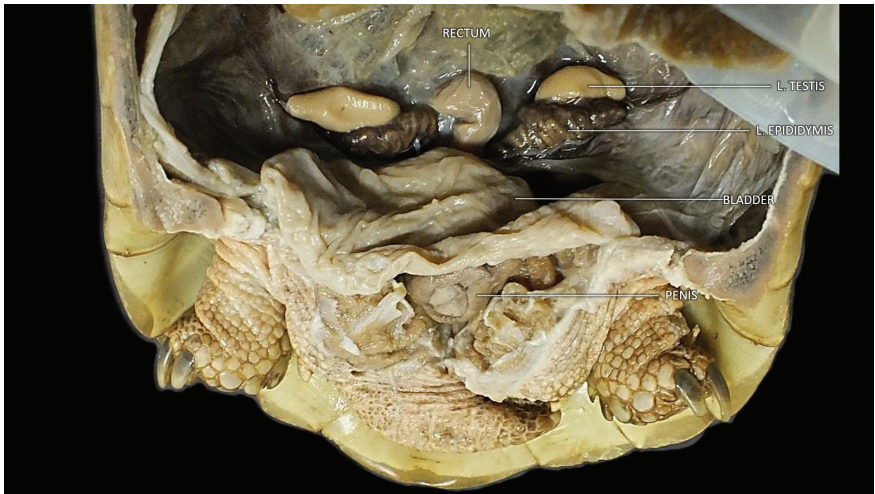

Fig. 4. Labeled prosection of full male reproductive anatomy.

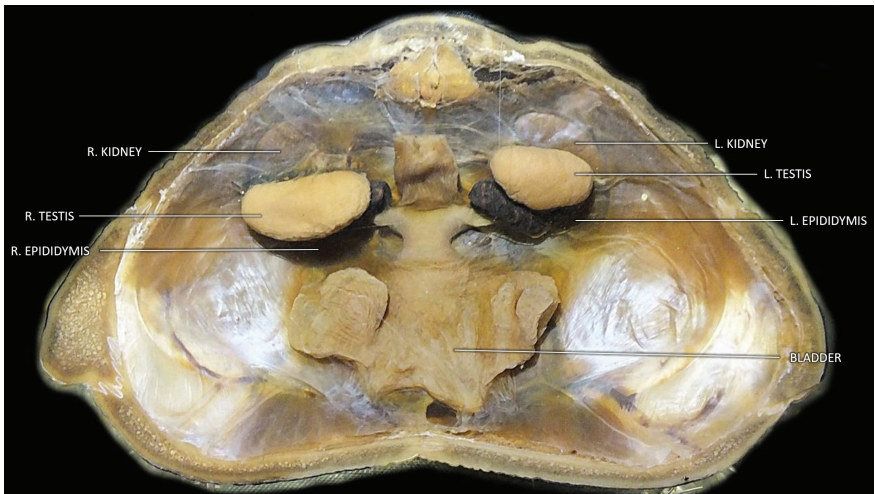

Fig. 5. Labeled prosection of male reproductive tract with kidneys.

the current chelonian collection and enabling it to be more accessible, whilst still protecting the integrity of the original specimens is an important step in preserving the collection. The online resource provides wider access which allows more people to learn and appreciate the finer details of chelonian anatomy.

Acknowledgements

I would like to thank the British Chelonia Group for funding the project via the Dick Smith Memorial Fund and ensuring that the chelonia specimens will be preserved for educational purposes.

Reference

O'Malley, B. (2005). *Clinical anatomy and physiology of exotic species: Structure and function of mammals, birds, reptiles and amphibians*. Elsevier Saunders, Edinburgh.