

# A pre-femoral approach to surgically treating pre-ovulatory follicular stasis in a marginated tortoise

Sonya Miles BVSc CertAVP(ZM) MRCVS  
RCVS Recognised Advanced Practitioner in Zoological Medicine

Presented to the BCG Symposium at the Open University, Milton Keynes on 16th March 2019

A 15-year-old, female marginated tortoise (*Testudo marginata*) presented with a two-month history of anorexia and hind limb lameness, and as a presumed male Hermann's tortoise (*Testudo hermanni*) by the owner. During the clinical history taking it became apparent that the care of the tortoise for her entire life had been substandard, with inadequate heat, ultraviolet (UV) light, calcium supplementation and diet being provided. She was confined to a garden with no supplementary heat or UV light, where she inappropriately self-hibernated for extensive periods of time (often six-eight months at a time). The tortoise had also never been bathed or provided with any water due to the owner's misunderstanding that tortoises get all the fluid they need from their diet.

On clinical examination the sex and species of the tortoise were identified. The tortoise weighed 1.5kg and was very weak, putting up no fight when her mouth and head were examined. She was lame on both of her hind legs to the point that she was unable to lift herself up for long, and dragged her plastron along the floor after only a few steps. She had pale mucous membranes but showed no sign of respiratory disease or stomatitis on examination. The rest of her clinical examination was unremarkable.

The tortoise was admitted for emergency hospitalisation, which involved placing her in a tortoise table that was set up to her preferred optimum temperature range using a radiant heat source (22-24°C at the cool end and 32-34°C at the basking end, with temperatures not dropping lower than 22°C at night). UV light of a suitable percentage (12%), and brand (Arcadia T5 strip bulb) was also provided. An intravenous catheter was placed into her right jugular vein to provide her with warmed fluid therapy (20ml/kg/day split into equal boluses every four hours). Regular Reptoboost (Vetark) bathing was started (twice daily for 15 minutes) whilst investigations were performed and a clinical plan was formulated. The tortoise was started on ceftazidime (Fortum, GSK) 20mg/kg to be given every 72 hours intramuscularly for eight consecutive doses prior to surgical intervention (and afterwards), and once she was warmed to her preferred optimal temperature.

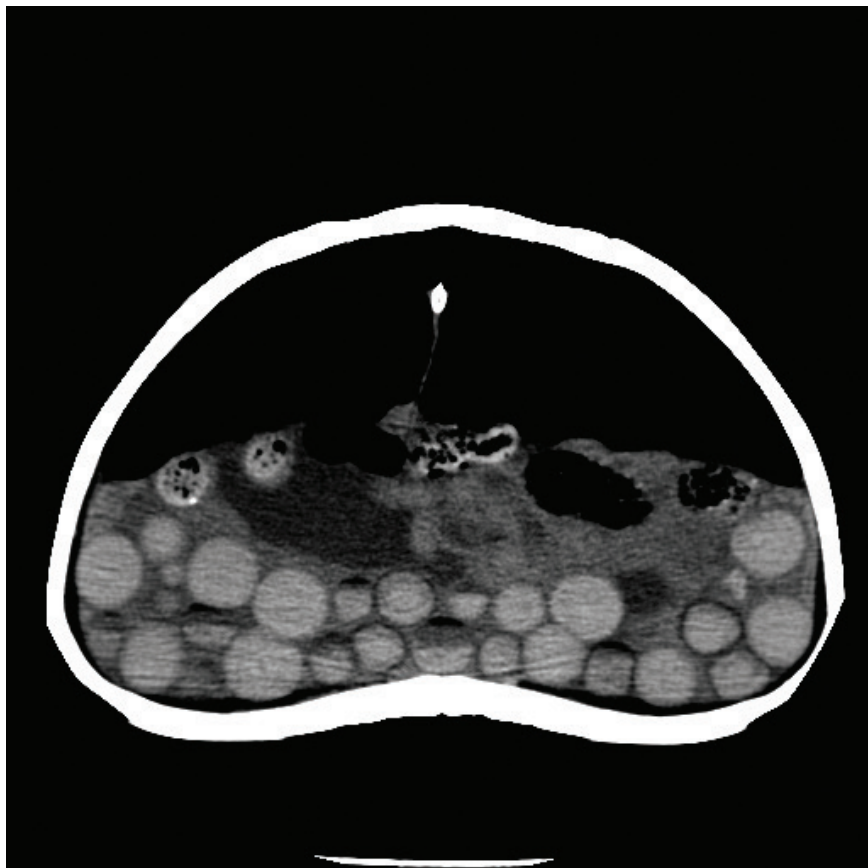


Fig. 1. A CT scan image of the tortoise demonstrating a significant number of follicles of various sizes.

Full biochemical and haematological profiles were performed by taking blood from the right jugular catheter to avoid lymphatic dilution (often obtained when sampling from other sites). A full body CT scan under a mild sedation was also performed. Severe dehydration (but with normal renal function), signs of reproductive activity (increased albumin, total protein, phosphorous and calcium levels), a marked toxic heterophillia and monocytosis were discovered via the blood tests, indicating an infection. When analysing the CT scan a very large number of abnormal follicles were noted in the coelomic cavity. No adhesions were present, nor was there free coelomic fluid (Fig. 1). Her preferred optimum temperature was maintained and monitored with a digital thermometer throughout all procedures.

In light of the blood and imaging results a pre-femoral window approach




Fig. 2. The tortoise placed in dorsal recumbency with her leg tied back allowing good visualisation and access to the pre-femoral fossae.

to the coelomic cavity was performed to allow an ovariosalpingectomy to be undertaken, as well as to allow in-depth assessment of the coelomic cavity with an endoscope and to allow endoscopic liver biopsies if they were deemed necessary.

The tortoise was premedicated with 1mg/kg morphine (Morphine, Martindale Pharmaceuticals) intramuscularly, left for 60 minutes, then induced with alfaxalone (Alfaxan, Jurox) 10mg/kg intravenously via the indwelling cannula. The tortoise was intubated and mechanically ventilated to maintain anaesthesia using 3-5% sevoflurane (SevoFlo, Abbott Laboratories) in 2 litres/minute of oxygen. She was placed in dorsal recumbency and had her legs tied in a fashion that allowed good visualisation and access to the pre-femoral fossae (Fig. 2).

After the surgical sites were cleaned with a diluted iodine solution, the skin of the pre-femoral fossae was incised creating a two centimetre opening. The underlying muscle layers and then the coelomic membrane were then opened in a similar fashion, to open the coelomic cavity (Fig. 3) and expose the reproductive tract which became immediately visible (Fig. 4). The oviduct was gently manipulated out of the hole, which was created on one side initially, until it was fully exteriorised. The mesovarium was then ligated employing a Ligasure (Medtronic), i.e. small metallic clips that are used to ligate blood vessels, and the ovaries and associated follicles were removed (Fig. 5). This process was performed bilaterally. Removal of the oviductal tissue does not need to be performed unless there is an obvious disease process; however, with this approach, if it is not removed it obscures the visual surgical field significantly.

Once all the reproductive tissue was removed, a sterile endoscope was inserted into both of the incisions and the coelomic cavity was explored. This is done to ensure that no follicles have fallen off and are left behind. It also allows a gross assessment of the viscera, specifically the liver, to be performed. In this case the liver was grossly normal. If it was not, then an endoscopic liver biopsy for histopathology would have been taken prior to closure, to investigate the extent of the disease process present.

The coelomic membrane was then closed with a simple continuous pattern of 4/0 poliglecaprone (Monocryl, Ethicon). The muscle layers were then closed with the same pattern and suture material. The skin was closed with 3/0 polydioxanone (PDS, Ethicon) in an interrupted, everting pattern, i.e. a horizontal mattress suture (Fig. 6). Before the tortoise was recovered from anaesthesia, a pharyngostomy tube was placed to aid in the application of medication and support feeding.

After two days of continued analgesia using 1mg/kg morphine (Morphine, Martindale Pharmaceuticals) intramuscularly every other day, and meloxicam (Metacam, Boehringer Ingelheim) at 0.5mg/kg via the feeding tube daily, the tortoise was sent home with continued meloxicam. The course of ceftazidime 20mg/kg to be given every 72 hours was continued for eight injections in total. The tortoise was eating immediately post-surgery; however, for seven days post-surgery, 2% of the tortoise's body weight in

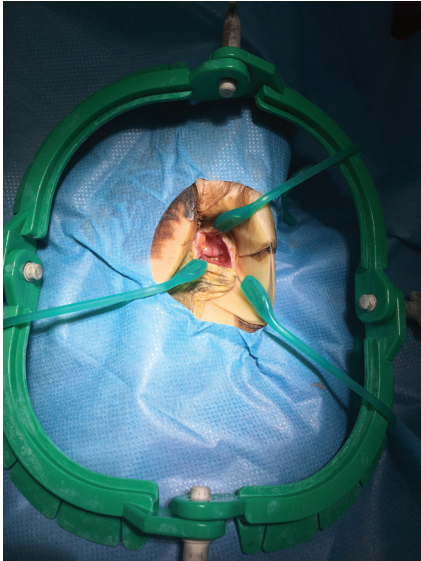


Fig. 3. Demonstrating the surgical site when performing a pre-femoral approach to coelomic surgery. A Lone Star® retractor is used to hold the tissues open.

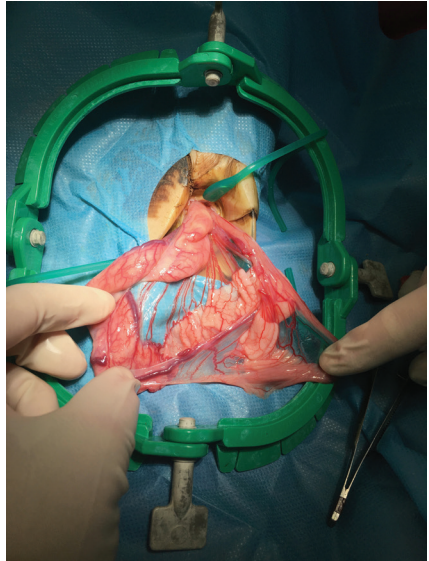


Fig. 4. Demonstrating the oviduct, which becomes immediately evident when performing a pre-femoral approach to coelomic surgery.

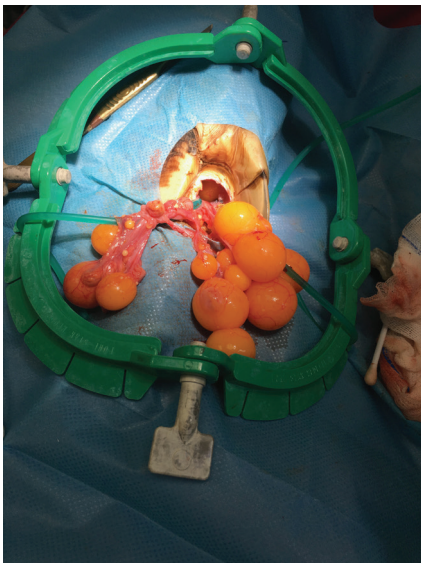


Fig. 5. Demonstrating one ovary with associated follicles that was exteriorised with gentle traction.



Fig. 6. Demonstrating the closed surgical site on one of the pre-femoral fossae. Only two sutures were needed to close each surgical site.

volume of Lafeber's Herbivore Critical Care food was given twice daily via the pharyngostomy tube, flushed before and after with 5ml of warmed tap water. The pharyngostomy tube was then removed and oral medications continued on her feed. Her sutures were removed six weeks after surgery and she has made a complete recovery.

Performing an ovariosalpingectomy via the pre-femoral approach is not always a possibility and in this author's opinion should only be considered in those cases where it is deemed safe to do so. In cases where adhesions are noted (usually based on advanced imaging such as CT scans) that would prevent all the reproductive tract from being exteriorised, or when severe liver disease has been diagnosed (usually with a combination of imaging and blood sampling) that may lead to coagulopathies that would cause bleeding that would be hard to control through this approach, this author recommends a plastrotoomy approach.

In the experience of this author, with the pre-femoral approach, the post-surgical recovery time is vastly reduced in comparison with a plastrotoomy approach. A significant proportion of the tortoises that have had coelomic surgery performed via this route return to normal eating activity within 24-48hrs of surgery, in comparison to weeks with the plastrotoomy approach. Healing time is also much reduced, with skin sutures used in the pre-femoral approach being removed after four to six weeks. Bone healing in the plastrotoomy approach can take months to years, especially in adult, full grown tortoises.

To the knowledge, and in the opinion of this author, this approach to coelomic surgery is more technically challenging, and is only offered by a small selection of exotic species vets throughout the United Kingdom and the world. It can sometimes take longer to perform coelomic surgery this way, compared to the historical plastrotoomy approach; but despite its challenges and the length of time it takes to complete, the benefits of performing coelomic surgery via the pre-femoral approach vastly outweigh the drawbacks, with the significantly shorter recovery time being the main advantage.